



## Case Report

# Pelvic pseudotumor following total hip arthroplasty – case report<sup>☆,☆☆</sup>



Nelson Franco Filho<sup>a,b</sup>, Alexandre de Paiva Luciano<sup>a,b,\*</sup>, Bruno Vierno<sup>b</sup>

<sup>a</sup> Department of Medicine, Universidade de Taubaté (UNITAU), Taubaté, SP, Brazil

<sup>b</sup> Orthopedics and Traumatology Service, University Hospital of Taubaté, Taubaté, SP, Brazil

### ARTICLE INFO

#### Article history:

Received 18 September 2013

Accepted 7 October 2013

Available online 18 September 2014

#### Keywords:

Plasma cell granuloma

Hip arthroplasty

Pelvic neoplasms

### ABSTRACT

Loosening is a well-known complication of total hip arthroplasty. The accumulation of detritus resulting from mechanical wear forms inflammatory cells that have the function of phagocytizing this debris. Over the long term, these cells may give rise to a local granulomatous reaction. Here, we present a report on a case of pelvic pseudotumor subsequent to total hip arthroplasty, which is considered rare in the literature. The patient was a 48-year-old black man who started to be followed up medically eight months earlier because of uncharacteristic abdominal pains, dysuria and pollakiuria. He had undergone left total hip arthroplasty 17 years previously. Through clinical investigation and complementary examinations, an extra-articular granulomatous mass was diagnosed, constituting a pelvic pseudotumor.

© 2014 Sociedade Brasileira de Ortopedia e Traumatologia. Published by Elsevier Editora Ltda. All rights reserved.

### Pseudotumor de pelve pós-artroplastia total do quadril – relato de caso

#### RESUMO

A soltura é uma complicação bem conhecida nas artroplastias totais do quadril. O acúmulo de detritos resultante do desgaste mecânico forma células inflamatórias que têm a função de fagocitar esses detritos e podem, em longo prazo, gerar uma reação granulomatosa local. A seguir, apresentamos um relato de caso de pseudotumor de pélvis pós-artroplastia total do quadril, considerado raro na literatura consultada. Trata-se de paciente

#### Palavras-chave:

Granuloma de células plasmáticas

Artroplastia de quadril

Neoplasias pélvicas

<sup>☆</sup> Please cite this article as: Franco Filho N, de Paiva Luciano A, Vierno B. Pseudotumor de pelve pós-artroplastia total do quadril – relato de caso. Rev Bras Ortop. 2014;49(5):543-9.

<sup>☆☆</sup> Work developed in the Discipline of Orthopedics and Traumatology, Department of Medicine, Universidade de Taubaté, and in the Orthopedics and Traumatology Service, University Hospital of Taubaté, Taubaté, SP, Brazil.

\* Corresponding author.

E-mail: [alexandrepaiva76@ig.com.br](mailto:alexandrepaiva76@ig.com.br) (A. de Paiva Luciano).

<http://dx.doi.org/10.1016/j.rboe.2013.10.001>

2255-4971/© 2014 Sociedade Brasileira de Ortopedia e Traumatologia. Published by Elsevier Editora Ltda. All rights reserved.

de 48 anos, masculino, negro, que iniciou seguimento médico por dores abdominais incaracterísticas, disúria e polaciúria havia oito meses. Apresentava artroplastia total do quadril esquerdo havia 17 anos. Após investigação clínica e por meio de exames complementares, diagnosticou-se uma massa granulomatosa extra-articular, pseudotumor de pélvis.

© 2014 Sociedade Brasileira de Ortopedia e Traumatologia. Publicado por Elsevier Editora Ltda. Todos os direitos reservados.

## Introduction

Loosening is a well-known complication of total hip arthroplasty. The accumulation of detritus from mechanical wear forms inflammatory cells that have the function of phagocytizing this detritus. However, over the long term, formation of these cells may result in a granulomatous reaction. This has the effect of creating an abnormal additional joint mass and may lead to atypical joint or abdominal symptoms.

In the following, we report a case of loosening of an uncemented prosthesis in which an extra-articular granulomatous mass comprising a pelvic pseudotumor developed. In the literature, this condition is considered to be rare.

## Description of the clinical condition

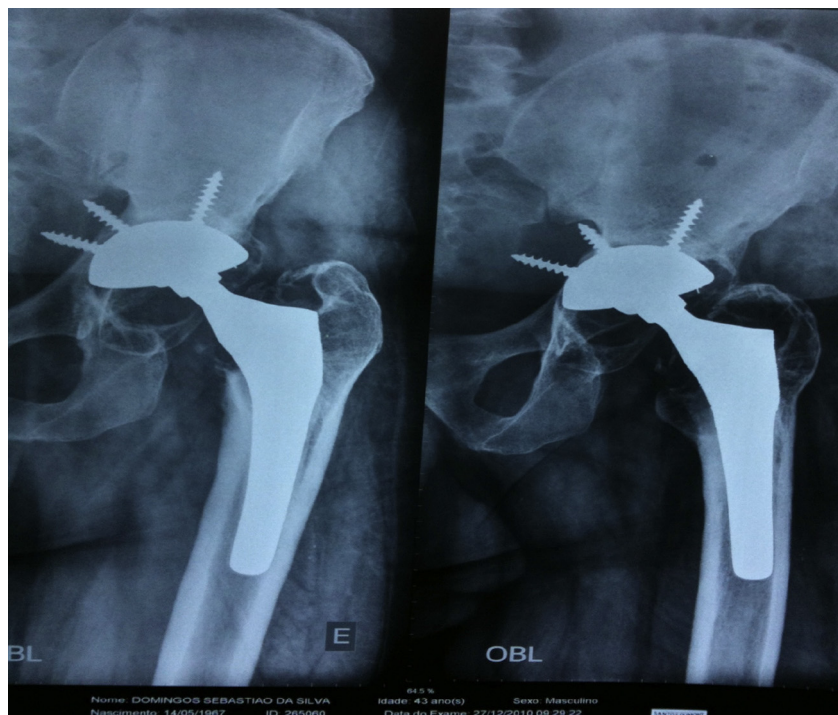
The patient was a 48-year-old black man who started to undergo medical follow-up because of abdominal pain irradiating uncharacteristically to the left hip, along with dysuria and pollakiuria, which he had had for eight months. He had undergone total hip arthroplasty 17 years earlier.

At a consultation with an urologist, no irregularities or alterations were found through digital rectal examination. The patient underwent a prostate biopsy, which did not show any neoplastic alterations.

In the orthopedic physical examination on admission, the patient presented the following:

- Inspection: no gait abnormalities; presence of a surgical scar in the posterolateral region of the left hip;
- Bone palpation: no pain in the left or right hip;
- Range of motion of the left hip: flexion of 90°, extension of 20°, abduction of 25°, adduction of 15°, internal rotation of 20° and external rotation of 15°;
- Sensitivity present and no alterations to the lower limbs;
- Muscle strength of grade V in both lower limbs;
- Peripheral pulse present and full in the lower limbs;
- After the orthopedic clinical examination, an investigation using imaging examinations was conducted (Figs. 1-3).

With the aid of the imaging examinations, surgical treatment was then proposed, with intervention by two specialists during the same operation: from the urology service to



**Fig. 1** – Radiographs of the left hip in anteroposterior and oblique views (December 27, 2010) showing total arthroplasty performed 17 years earlier.

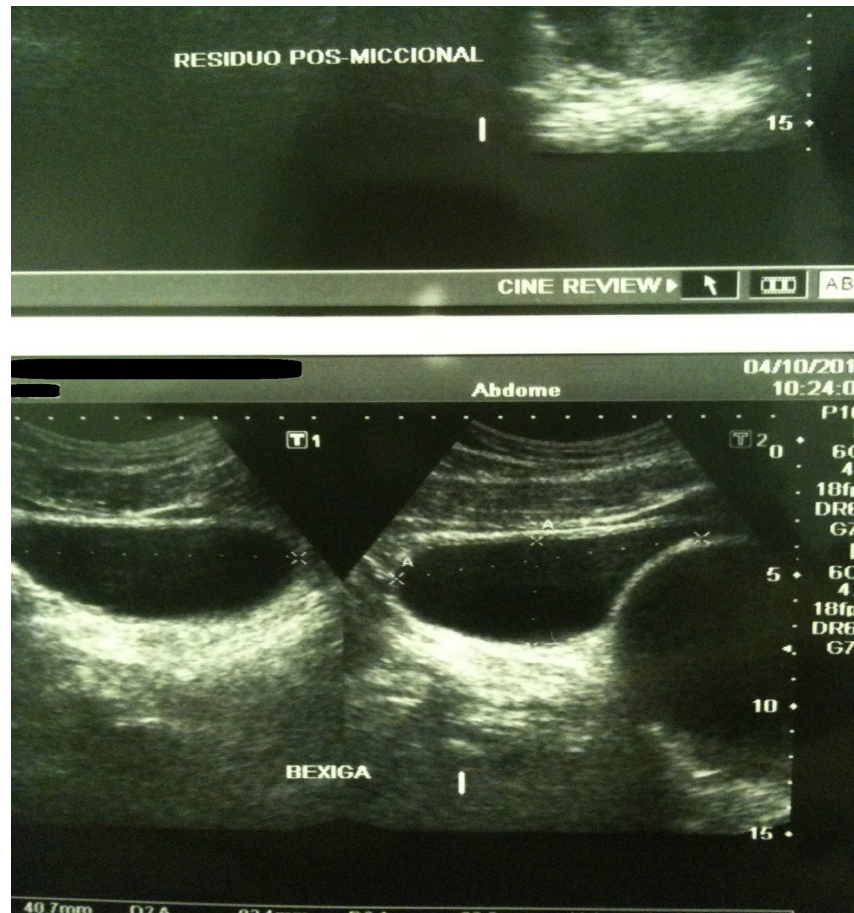


Fig. 2 – Echographic images of the urinary tract and prostate showing mass of cystic appearance close to the bladder.

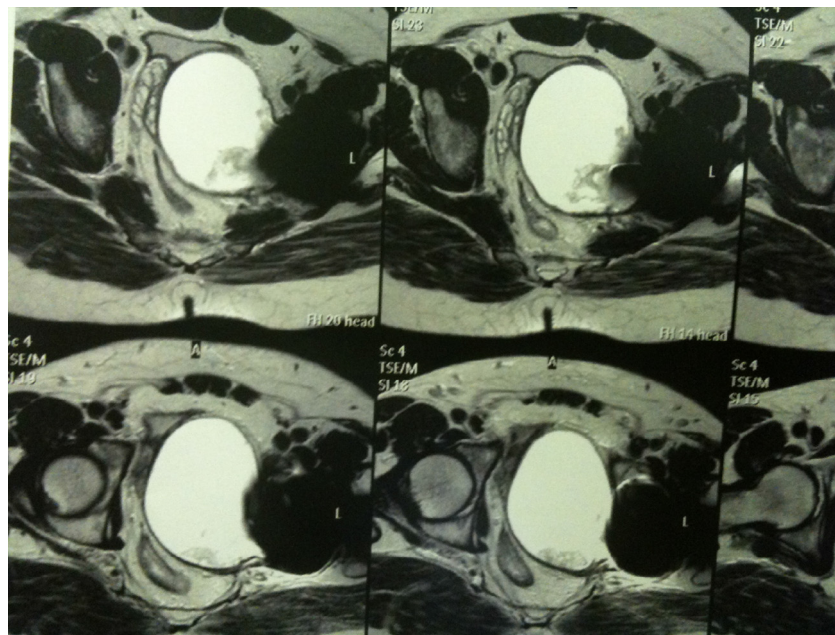
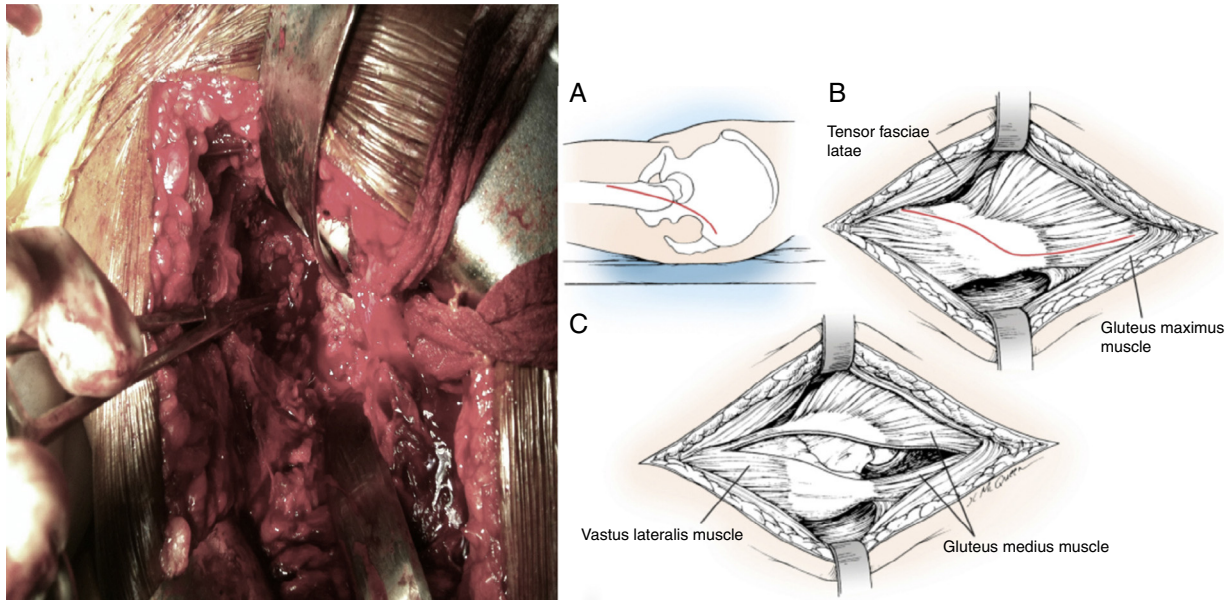


Fig. 3 – Magnetic resonance imaging in sagittal view with T1 weighting, showing presence of extra-articular mass of fluid appearance in the pelvis.



**Fig. 4 – Detail of the surgical procedure for revision of total hip arthroplasty and resection of the tumoral mass.**

perform decompression and resection of the mass; and from the joint reconstruction group to perform revision of the left-side total hip arthroplasty. These surgical procedures were carried out in February 2011 (Figs. 4 and 5).

After the surgical resection described above, the diagnosis was confirmed by means of anatomopathological examination, which showed the presence of granulomatous tissue with absence of neoplastic or infectious cells.

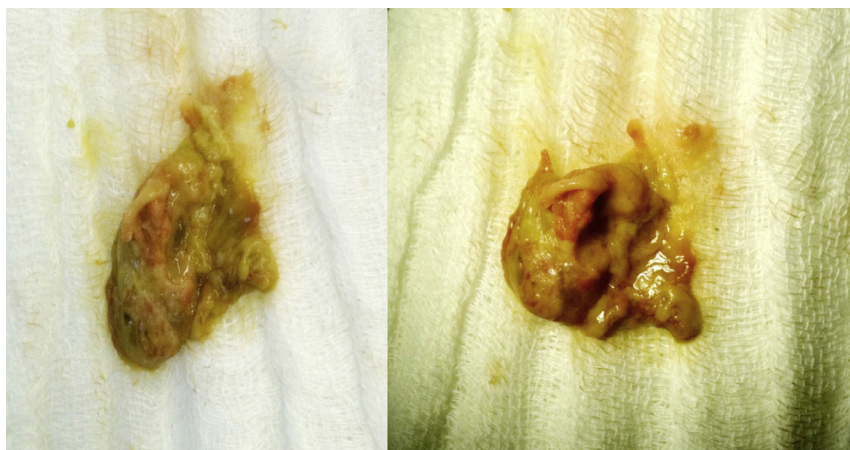
Eight months after the operation, control radiographs of the revision of the left-side total hip arthroplasty in anteroposterior and lateral views and control echographs of the urinary tract and prostate were produced. These were within normal patterns and demonstrated that there had not been any recurrence of the cyst (Figs. 6 and 7).

## Discussion

Clinical and radiographic signs of induced osteolysis are frequently seen in relation to hip prostheses, and these

complications are well-known among hip surgeons. However, a less common complication may accompany such events: presence of a mass of symptomatic soft tissue. In our case, the patient presented initial symptoms relating to urological alterations, without signs or symptoms in the hip joint.

Detritus resulting from loosening or wear is usually phagocytized by macrophages and inflammatory cells. In certain situations, an aggressive granulomatous reaction may occur, with the characteristics of a foreign body. This reaction is characterized clinically by formation of progressive cysts that generate symptomatic masses in the pelvis.<sup>1,2</sup> Santavirta et al.<sup>3</sup> suggested that this granulomatosis would involve decoupling of the normal sequence of “monocytes-macrophages-clearance”, mediated by foreign materials and tissue detritus, which is normally followed by fibroblasts. Schmalzried and Callaghan<sup>4</sup> reported that this aggressive lysis could occur at any point along the space of the hip joint. A defect in the joint capsule or a bone defect may result in herniation or in propagation of this space to the extra-articular



**Fig. 5 – Resected anatomical specimen.**

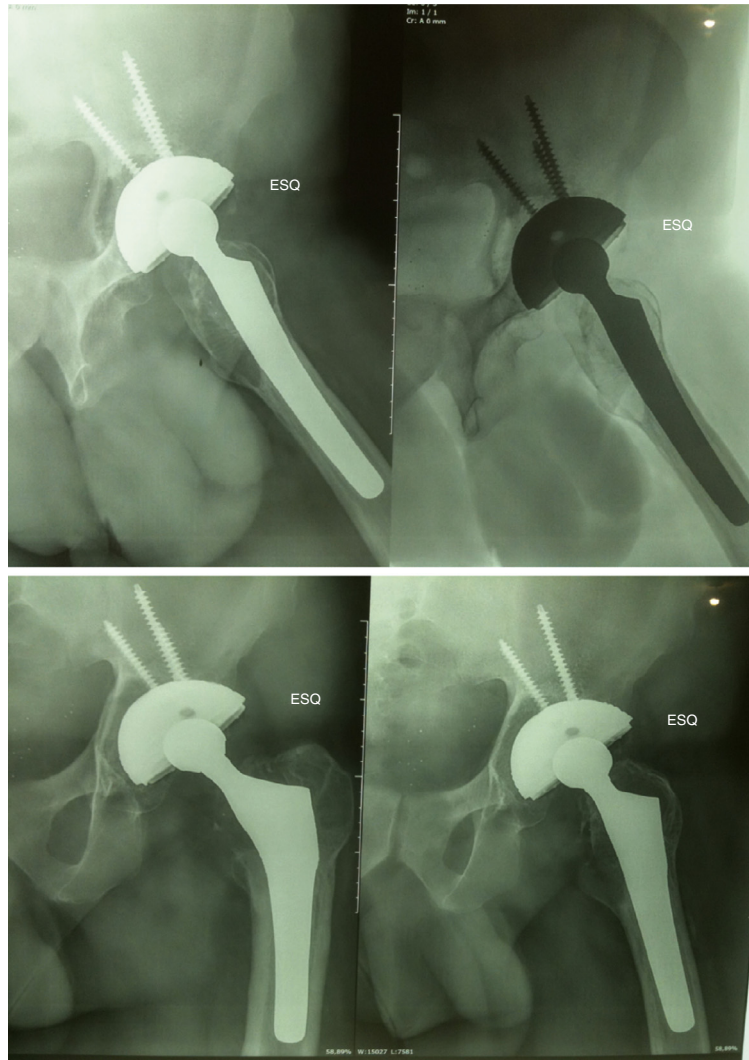


Fig. 6 – Postoperative control radiographs in anteroposterior and lateral views, produced eight months after revision of the left-side total hip arthroplasty.

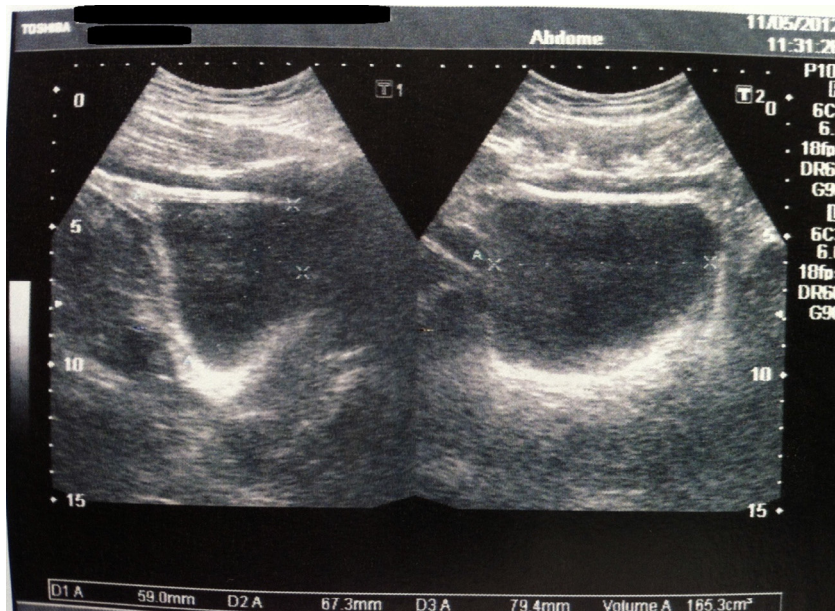


Fig. 7 – Postoperative control echographs of the urinary tract and prostate, within normal patterns.

**Table 1 – Summary of diagnoses and management of similar cases.**

Authors	Age	Type of prosthesis	Number of years until revision	Symptoms	Diagnosis	Cyst management	Prosthesis management	Number of incisions
Hartrup et al. <sup>7</sup>	59	Cemented revision due to infection	7 years since revision	Dysuria and nocturia	Acetabular loosening and migration	Laparotomy with cyst excision	Revision of total hip prosthesis	2
Reigstad and Rokkum <sup>8</sup>	78	Cemented revision/loosening	6 years since revision	Mass in right iliac fossa	Migration of acetabulum inside pelvis	Extraperitoneal excision of the cyst	Revision of total hip prosthesis	2
DeFrang et al. <sup>9</sup>	57	Uncemented	3 years	Edema and pain in lower limb	Wear on polyethylene	Ilioinguinal excision of the cyst	Revision one year after total hip prosthesis	2
Matsumoto et al. <sup>10</sup>	58	Cemented	21 years	Ileocecal pain and mass	Loosening and migration of acetabulum	Retroperitoneal excision	Revision of total hip prosthesis + bone grafting	2
Fischer et al. <sup>11</sup>	84	Uncemented	5 years	Pain and weakness in lower limb	Compression of sciatic nerve	Debridement	Revision of total hip prosthesis	1
Madan et al. <sup>12</sup>	83	Cemented revision/loosening	14 years since revision	Acute pain and edema in hip	Compression of femoral artery and vein	Inguinal excision and subsequent retroperitoneal	Revision and grafting in total hip prosthesis	3
Hisatome et al. <sup>13</sup>	46	Cemented Charnley	16 years	Hip pain	Acetabular defect	Resection of mass	Acetabular revision	1
Hisatome et al. <sup>13</sup>	46	Bipolar arthroplasty	15 years	Right-side inguinal mass	Acetabular osteolysis	Resection of mass	Cemented revision of total hip prosthesis	1
Korkala and Syrjanen <sup>14</sup>	56	Cemented	10 years	Right-side inguinal mass	Acetabular osteolysis	Aspiration of cyst	Revision and grafting in acetabulum	1
Wang and Lin <sup>15</sup>	50	Uncemented revision	5 years since revision	Left-side inguinal mass	Defect of acetabular wall	Debridement of mass	Revision and grafting in acetabulum	1

Translated and adapted from Leigh W, O'Grady P, Lawson EM, Hung NA, Theis JC, Matheson J. Pelvic pseudotumor: an unusual presentation of an extra-articular granuloma in a well-fixed total hip arthroplasty. *J Arthroplasty*. 2008;23(6):934-8.

region.<sup>5,6</sup> In our patient, this mass was concentrated in the extra-articular space. Granulomatous masses of this nature in the pelvis may be symptomatic or asymptomatic. They may be identified during routine investigations for other reasons or may become evident during the preoperative investigations for hip revision surgery.<sup>7</sup> In our patient, revision of the prosthesis was indicated only for removal of the cyst. The lesion may cause symptoms, resulting from pressure on adjacent structures, which did not occur in this patient. In this case, the pelvic mass caused abdominal pains with uncharacteristic irradiation to the left hip, accompanied by dysuria and pollakiuria.

For the purposes of making comparisons with the present case, Table 1 shows a summary of diagnoses and management approaches used in similar cases.

### Conflicts of interest

The authors declare no conflicts of interest.

### REFERENCES

- Zicat B, Engh CA, Gokcen E. Patterns of osteolysis around total hip components inserted with and without cement. *J Bone Joint Surg Am*. 1995;77(3):432-9.
- Jacobs JJ, Shanbhag A, Glant TT, Black J, Galante JO. Wear debris in total joint replacements. *J Am Acad Orthop Surg*. 1994;2(4):212-20.
- Santavirta S, Konttinen YT, Bergroth V, Eskola A, Tallroth K, Lindholm TS. Aggressive granulomatous lesions associated with hip arthroplasty: immunopathological studies. *J Bone Joint Surg Am*. 1990;72(2):252-8.
- Schmalzried TP, Callaghan JJ. Wear in total hip and knee replacements. *J Bone Joint Surg Am*. 1999;81(1):115-36.
- Mak KH, Wong TK, Poddar NC. Wear debris from total hip arthroplasty presenting as an intrapelvic mass. *J Arthroplasty*. 2001;16(5):674-6.
- Morrison KM, Apeltgren KN, Mahany BD. Back pain, femoral vein thrombosis, and an iliopsoas cyst: unusual presentation of a loose total hip arthroplasty. *Orthopedics*. 1997;20(4):347-8.
- Hatrup SJ, Bryan RS, Gaffey TA, Stanhope CR. Pelvic mass causing vesical compression after total hip arthroplasty: case report. *Clin Orthop Relat Res*. 1988;227:184-9.

8. Reigstad A, Røkkum M. An intrapelvic granuloma induced by acetabular cup loosening. *Acta Orthop Scand.* 1992;63(4):465-6.
9. DeFrang RD, Guyer WD, Porter JM, Duwelius PJ. Synovial cyst formation complicating total hip arthroplasty: a case report. *Clin Orthop Relat Res.* 1996;(325):163-7.
10. Matsumoto K, Hukuda S, Nishioka J, Fujita T. Iliopsoas bursal distension caused by acetabular loosening after total hip arthroplasty: a rare complication of total hip arthroplasty. *Clin Orthop Relat Res.* 1992;(279):144-8.
11. Fischer SR, Christ DJ, Roehr BA. Sciatic neuropathy secondary to total hip arthroplasty wear debris. *J Arthroplasty.* 1999;14(6):771-4.
12. Madan S, Jowett RL, Goodwin MI. Recurrent intrapelvic cyst complicating metal-on-metal cemented total hip arthroplasty. *Arch Orthop Trauma Surg.* 2000;120(9):508-10.
13. Hisatome T, Yasunaga Y, Ikuta Y, Takahashi K. Hidden intrapelvic granulomatous lesions associated with total hip arthroplasty: a report of two cases. *J Bone Joint Surg Am.* 2003;85A(4):708-10.
14. Korkala O, Syrjänen KJ. Intrapelvic cyst formation after hip arthroplasty with a carbon fibre-reinforced polyethylene socket. *Arch Orthop Trauma Surg.* 1998;118(1/2):113-5.
15. Wang JW, Lin CC. Pelvic mass caused by polyethylene wear after uncemented total hip arthroplasty. *J Arthroplasty.* 1996;11(5):626-8.